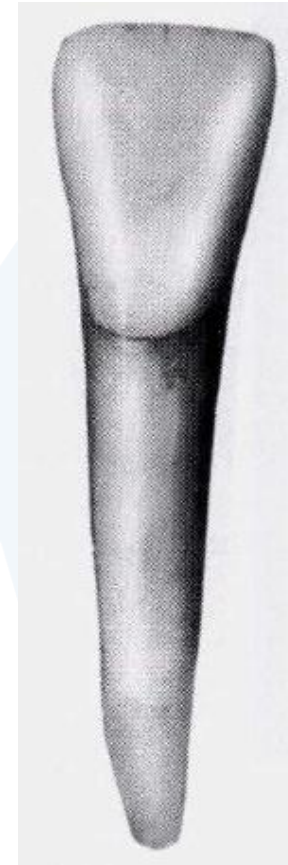



Mandibular Lateral Incisor

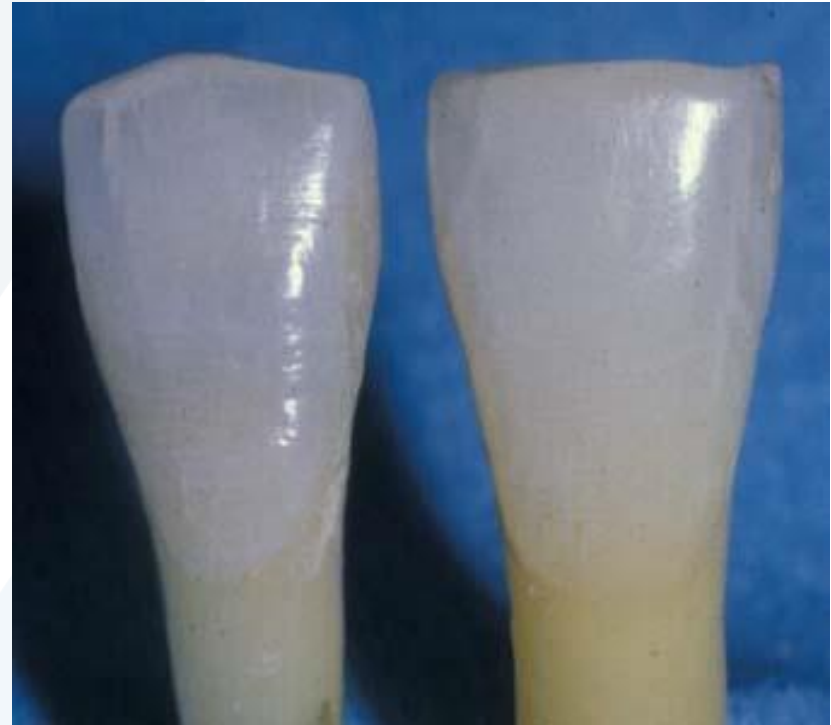Labial aspect

- It resembles the mandibular central incisor so closely.
- تَبْزُغُ فِي عَمْر 7-8 سَنَوَات
- The mandibular lateral incisor is the second mandibular tooth from the median line , left or right .



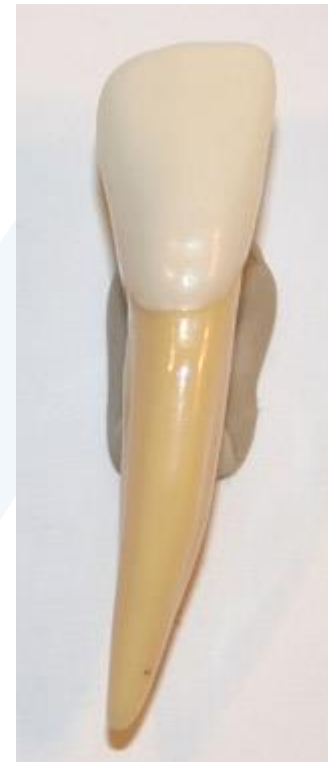Labial aspect

- Central incisors are more narrow than lateral incisors mesiodistally .



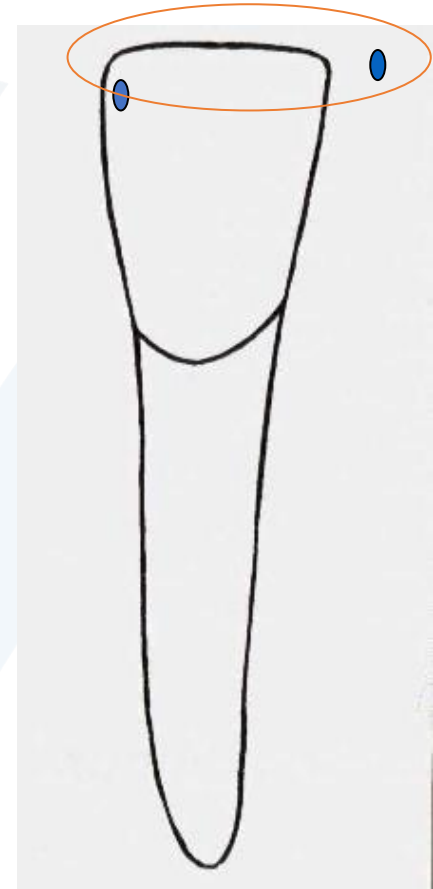
Labial aspect

- Mesial and distal surfaces are very flat, with a SLIGHT increase in convexity on the distal surfaces.



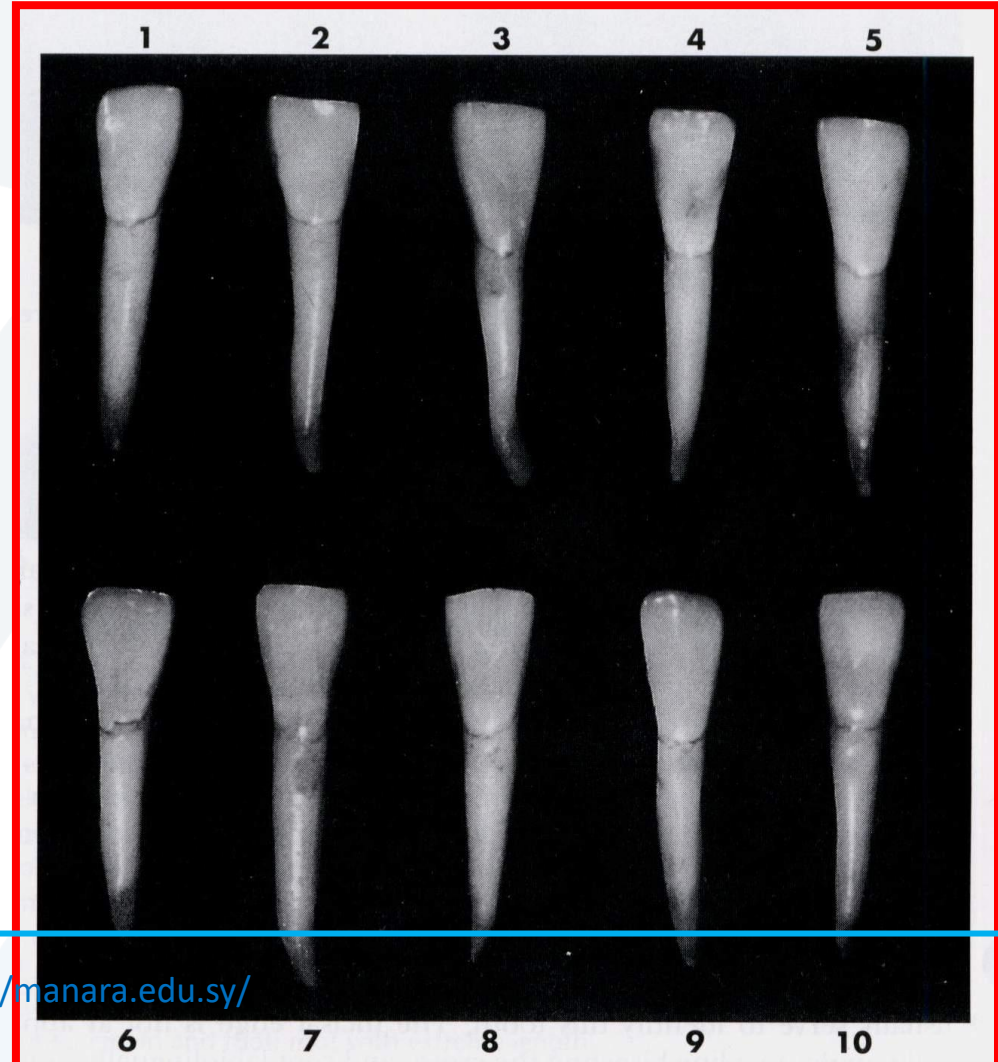Labial aspect

- **Mesial** and **distal** heights of contour of both centrals and laterals are located in the incisal 1/3.



Ten Typical specimens

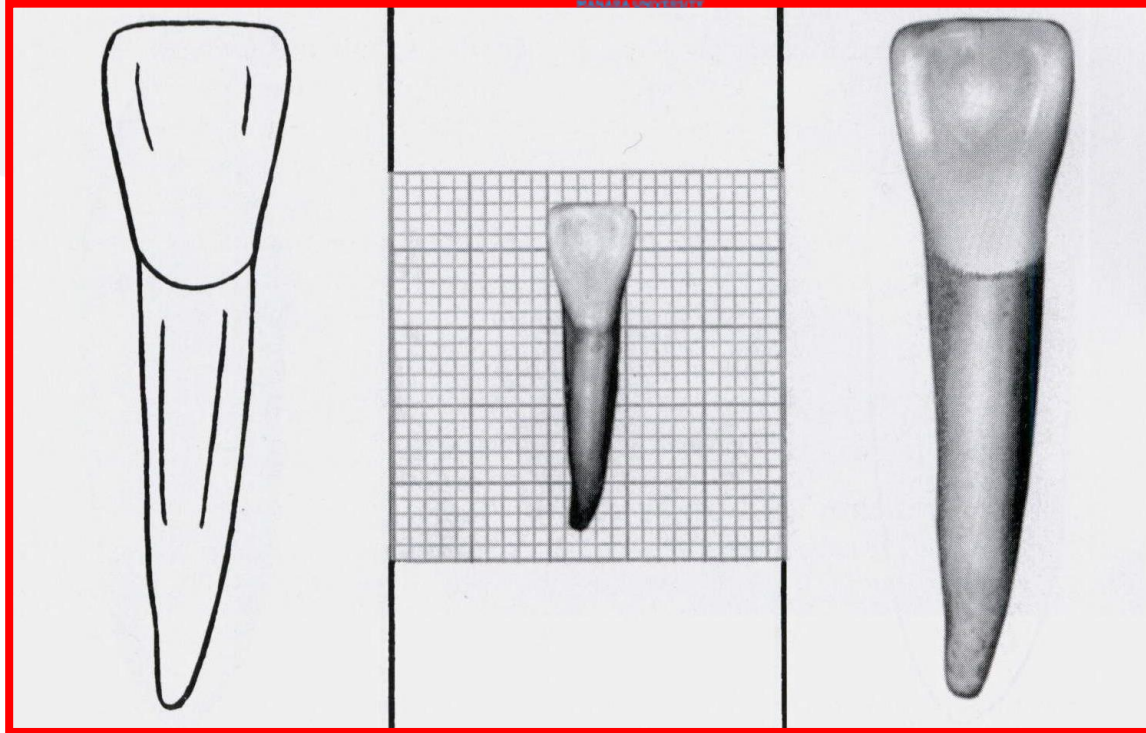
- Anatomical variation



Lingual aspect

- It resembles the mandibular central incisor so closely .

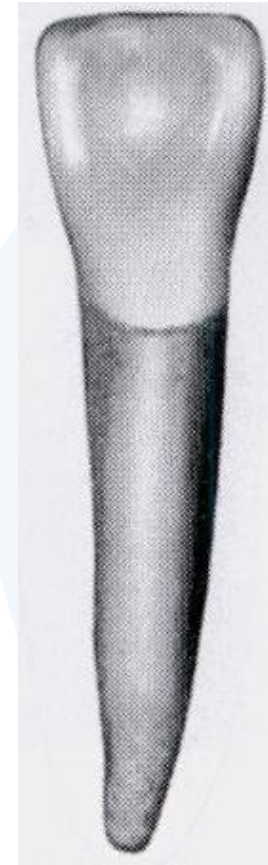



Rarely, it will have a labial and lingual root division in the cervical third . Somewhat more commonly they have two canals in the single root.


Lingual aspect

- Mesial and distal incisal angles of the mandibular lateral incisors are more rounded than those of the mandibular central incisors.



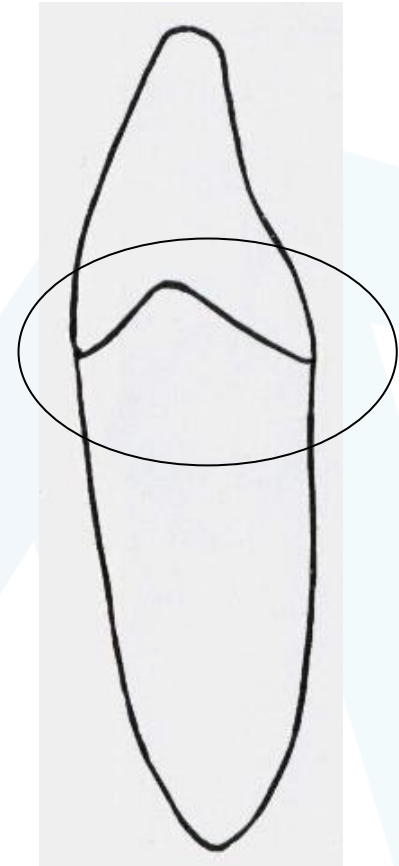
Lingual aspect

- **Heights of contour** are in the incisal 1/3 on proximal surfaces.



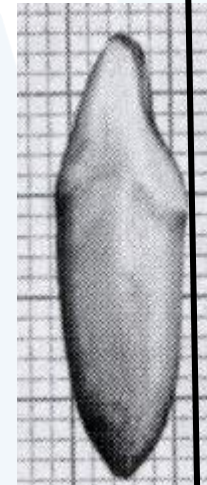
Mesial aspect

- Labial and lingual height of contour in the gingival 1/3.



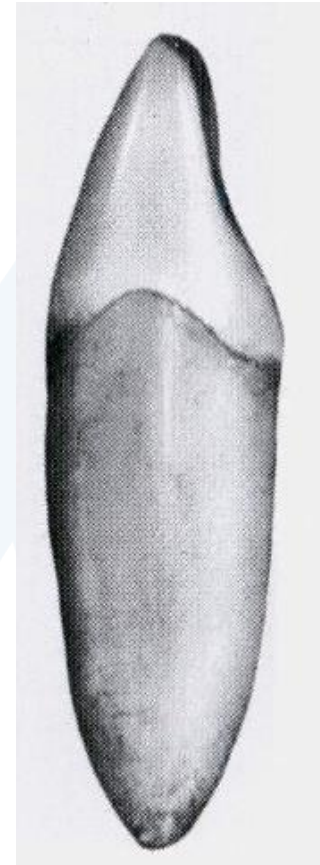
Mesial aspect

- Incisal ridge is positioned slightly LINGUAL of center.

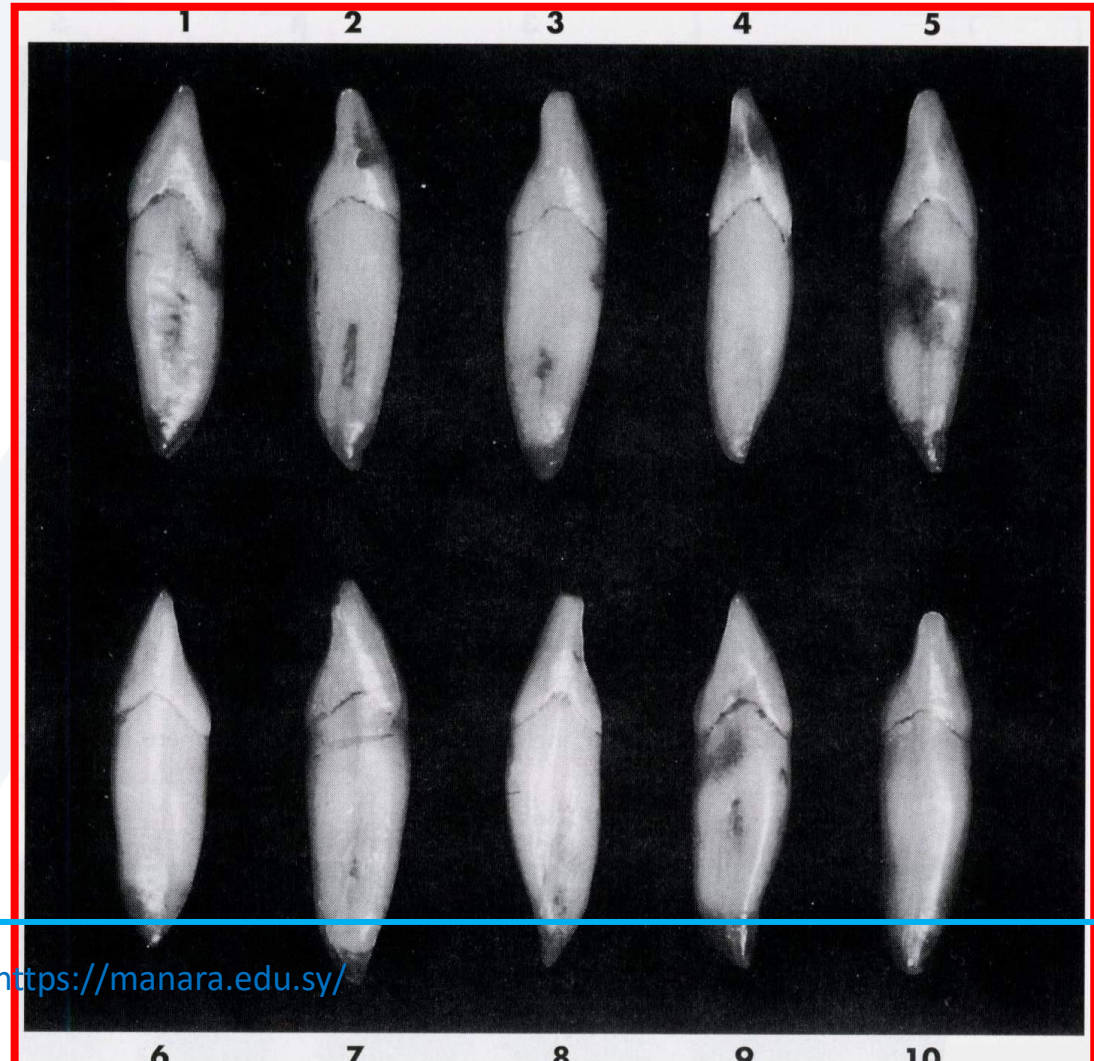


Mesial aspect

- The mesial side of the crown is often longer than the distal side ,causing the incisal ridge to slope downward in the distal direction .



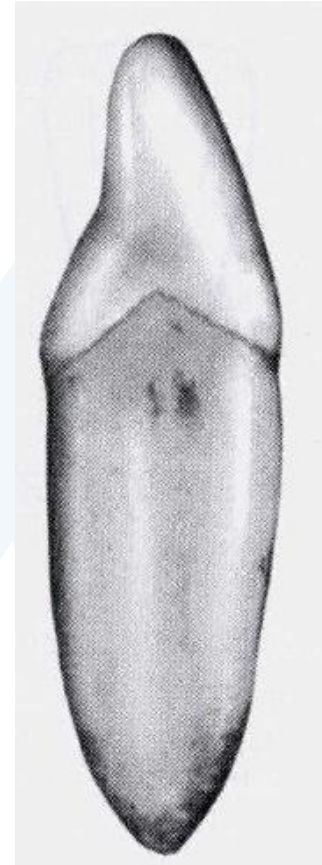
Ten Typical specimens



- Anatomical variation

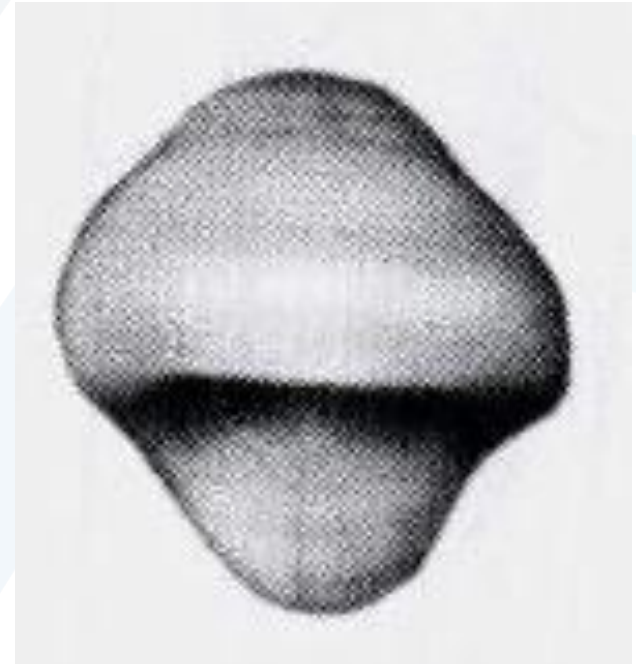
Distal aspect

- It resembles the mesial aspect.
- the crown ,from this aspect, is shorter than the mesial aspect.



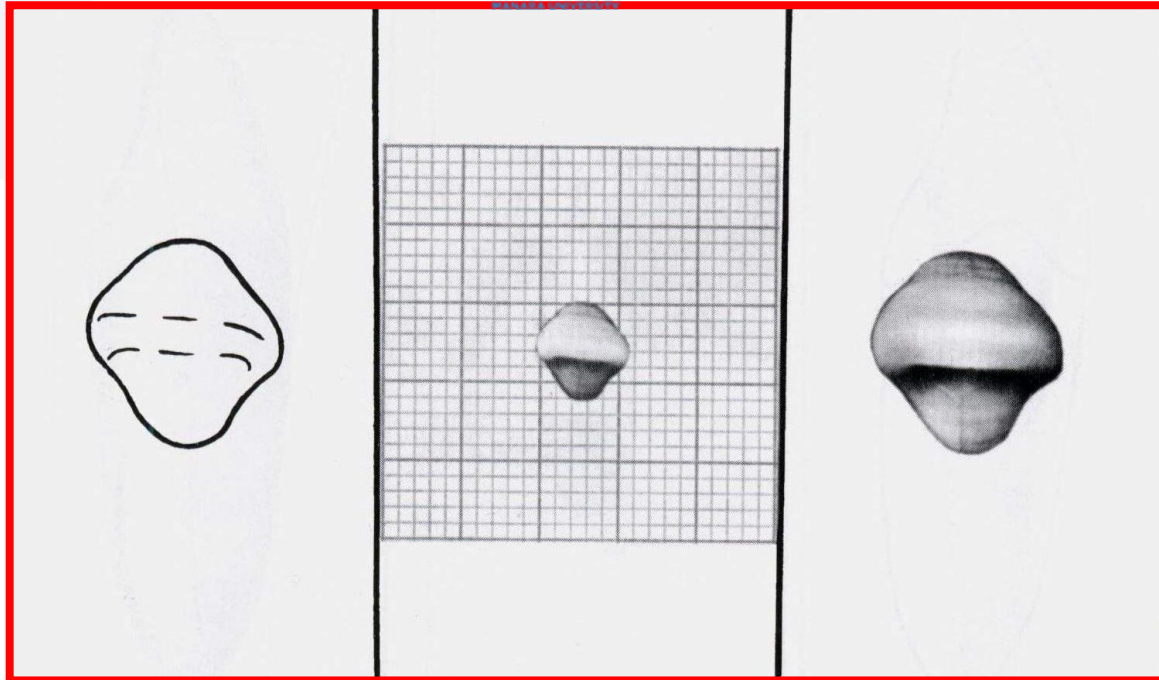
Incisal aspect

- Mandibular central and lateral incisors are almost identical in this view.





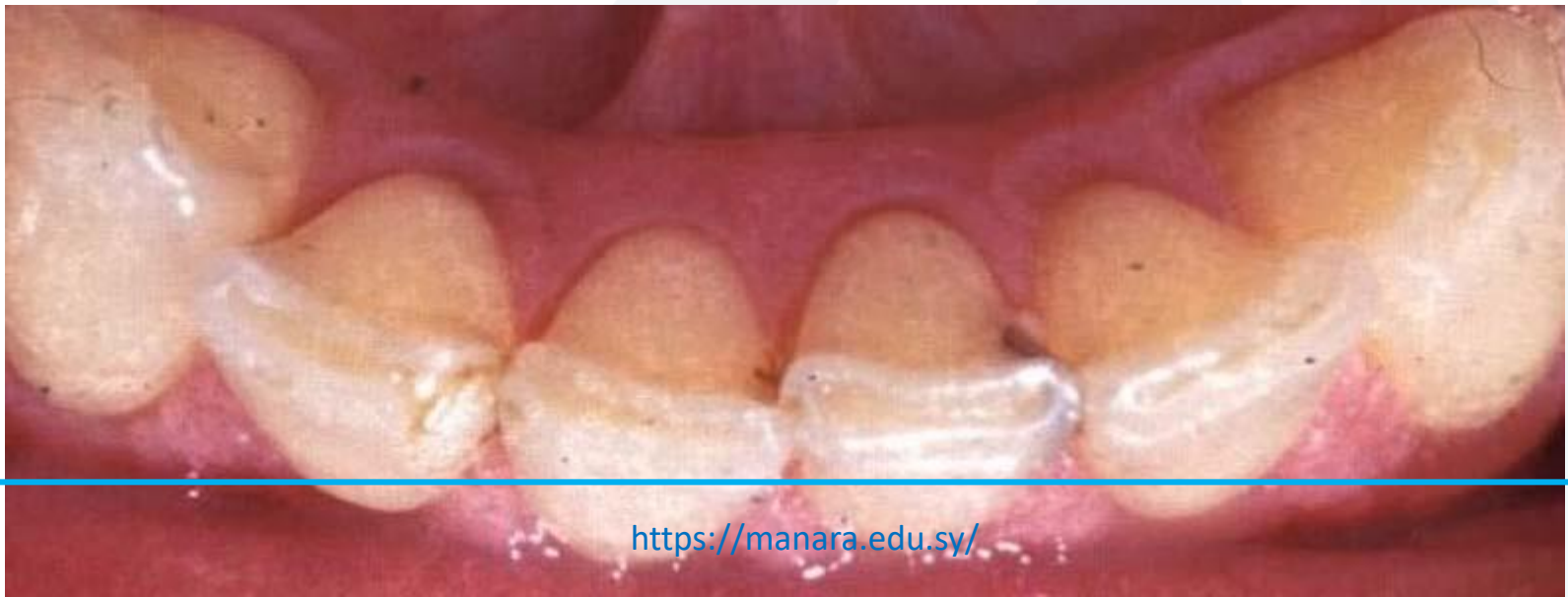جامعة
المنارة



Incisal Aspect: The edge follows the curvature of the mandibular arch giving the crown of this tooth the appearance of being twisted slightly on its root base .

Incisal aspect

- Lingual surfaces are smooth, free of pits or grooves .
- Lingual embrasures are longer (deeper) faciolingually than labial embrasures which are short and wide .

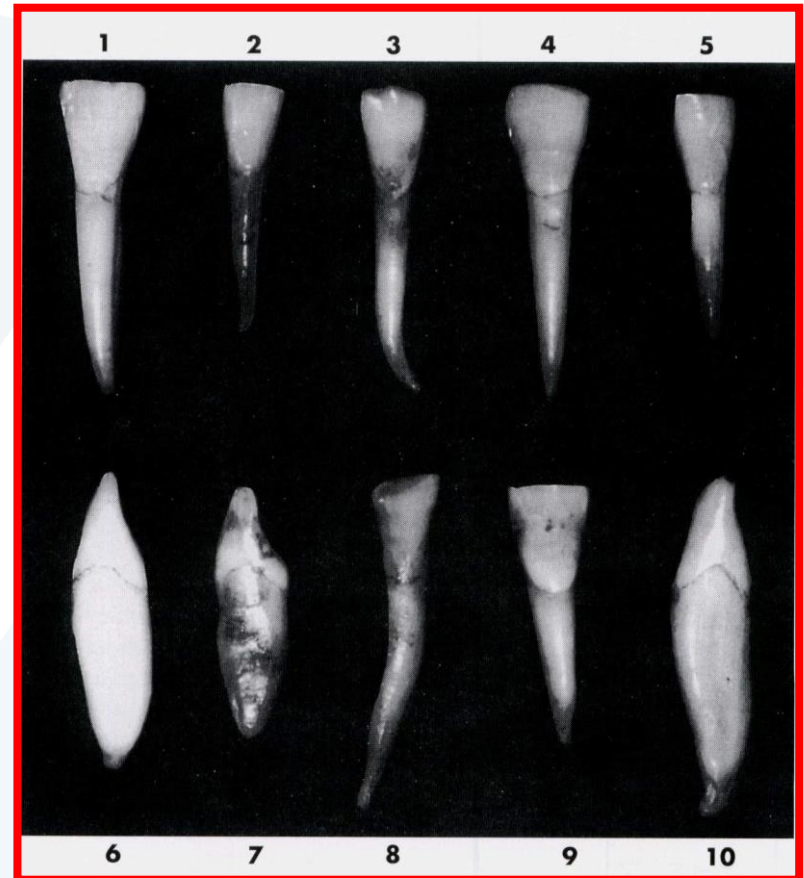


uncommon variations

1 - Tooth very large constricted in comparison with crown width.

2 - specimen well-formed ,smaller than average.

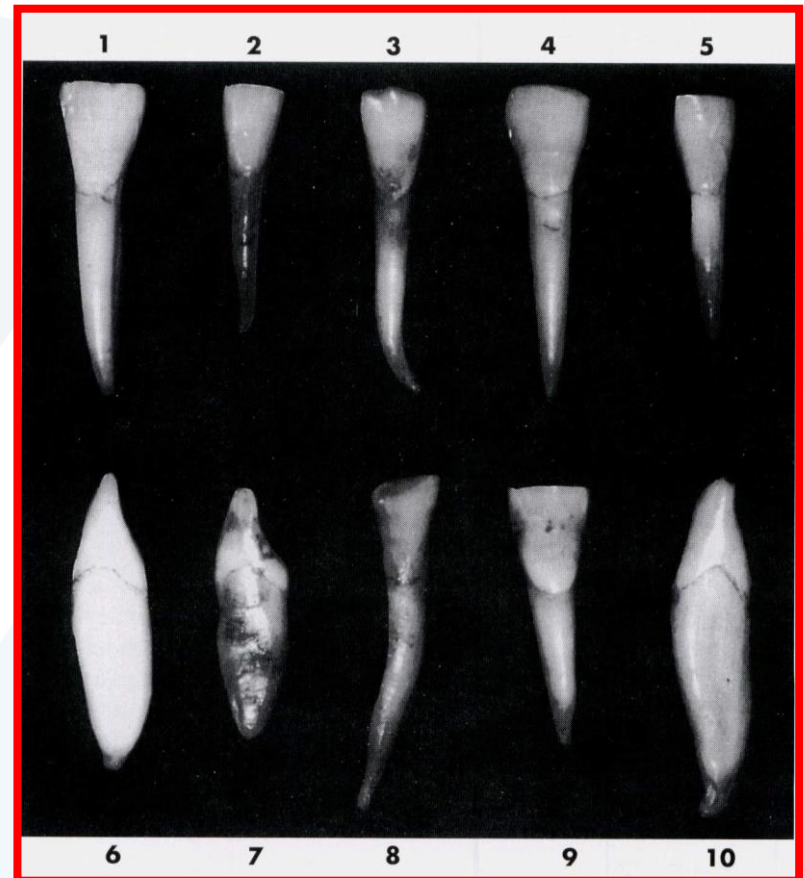
3 - Root extra long, extreme curvature at apical third.



uncommon variations

4 - Extreme mesiodistal measurement for crown length, contact areas very broad cervicoincisally.

5 - specimen undersized.

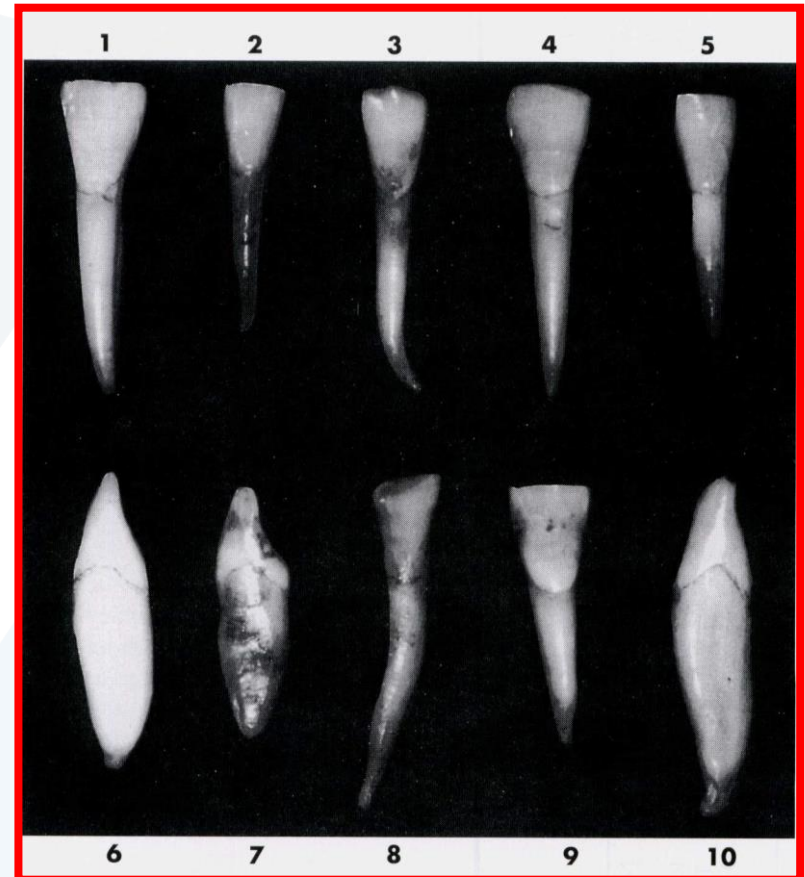


uncommon variations

6 - Incisal ridge thin ,little or no curvature at cervical third of crown.

7 - Incisal edge labial to center of root ,root rounded ,cingulum with more curvature above root than average.

8 - malformed crown and root, root with extreme length.



uncommon variations

9- crown very wide, root short

10-very slight curvature at the cervical third of the crown ,entire tooth oversized ,malformation at the root end.

